



Histological Pop Art: New Dimensions in Photomicrography

Anne U. Kerber^{1,*}, Jörg Piper², Thomas Vogt¹, and Cornelia S. L. Müller¹

¹Department of Dermatology, Saarland University Medical Center, D-66421 Homburg/Saar, Germany

²Clinic "Meduna," Department of Internal Medicine, Angiology, Cardiovascular Medicine, Clara-Viebig-Road No. 4, D-56864 Bad Bertrich, Germany

The authors demonstrate a special method of post processing, initially inaugurated by Anne Kerber, leading to improved color contrast even in structures of very low density which are barely visible in the respective original photomicrographs. This technique leads to results which can be regarded as complementary methods when compared with traditional methods in optical contrast enhancement. The potential of this special post processing is demonstrated by histological sections from normal human skin showing the structure of hair and surrounding tissues. The sections pass through various classical histological staining methods (in this case, Mallory's trichrome staining), and they are conventionally mounted with cover slips. In a first step photomicrographs are taken from areas of interest in various magnifications. By use of digital techniques and raster graphics editors, the images are then transformed in shape and color to new pictures characterized by a particular style. The underlying tissue structures are still clearly visible, but highlighted with their extraordinary variety of color and texture. Even structures of very low thickness or density are accentuated in variable multicolor contrast so that the techniques presented can be used for improved visualization of scientific tasks. Moreover, images of this sort have a high a grade of esthetical appeal so that they can also such histological "Pop Art" can also used for several tasks in decoration and interior design.

Keywords: Histology, Pop Art, Digital Image Processing, Histological Art, Dermatology, Hair.

1. INTRODUCTION

The term *histology* is derived from the two Greek words, *histos* (tissue) and *logos* (word, teaching); it is focused on the science of morphology and structure of biological tissues. In histology, very thin sections of tissue are prepared. For examination with a light microscope, their thickness ranges from 10–50 μm or 0.5–10 μm in so-called thin-layer sections. The histological sections of human skin shown in this paper are in the range of 3–5 μm . For routine examination, sections are dyed with various staining methods and then preferably evaluated in a bright-field microscope. A small probe (biopsy) from the human skin can usually be taken under local anesthesia; this is a rather minor procedure. The removed piece of tissue is often no larger than a grain of rice.

As the primary author works in a dermatopathology laboratory, small pieces of healthy skin, left over from the cutting process from time to time, are available for Pop Art-like creations of histological artwork. In particular, probes taken from the skin of the human head show a good

deal of hair. These little pieces of tissue are the feedstock of the author's project. Hairs and their surrounding tissues are characterized by an extraordinary structure. A hair consists of the hair shaft, the hair root with pigment cells, the nourishing blood vessels, sebaceous glands, and the hair muscle (*musculus arrector pili*). The whole arrangement is called the hair follicle. The hair shaft is a thin "yarn" of keratinized cells and is that portion of the hair that is visible and touchable on the surface. The hair shaft consists of three layers: cuticle, cortex, and marrow. The diameter of scalp hair is circa 0.04–0.12 mm. Fair, blond hair is normally thinner than dark or red hair. Cross-sections of hair may have different shapes; most of them appear round to slightly oval.

The beauty and artistic value of these special hair structures may not be seen at first glance. Many people will think: What art can be seen in a simple hair? Special techniques of digital imaging, however, transform glands, parts of hair, muscles, and such to artistic photographic works in the style of Pop Art. These are characterized by an intense, multifaceted color and accentuation of their special texture. Even zones that appear empty or show

*Author to whom correspondence should be addressed.

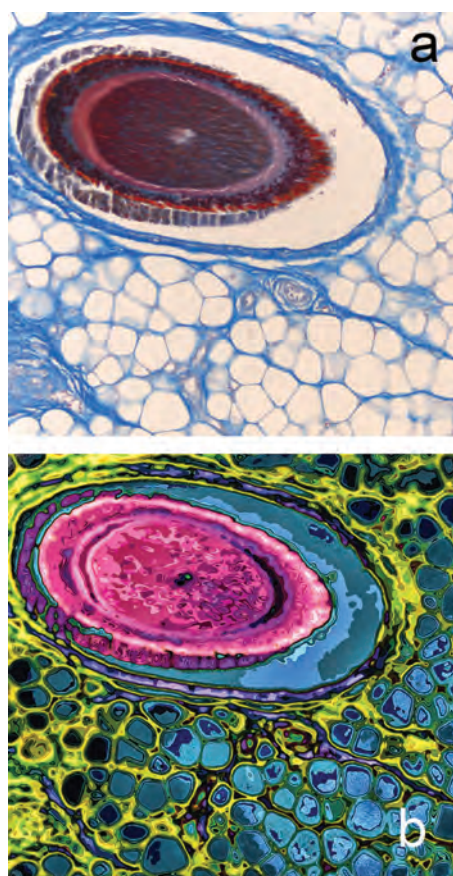


Fig. 1. Hair: cross section with surrounding fat and connective tissue; bright field (a), Pop Art style (b).

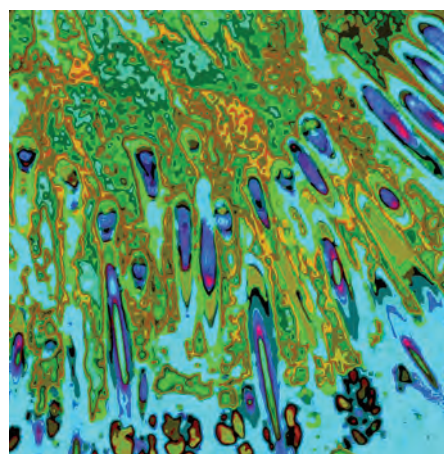


Fig. 3. Scalp: cross-section, overview.

negligible structure in bright-field microscopy are filled with multicolored forms in Pop Art–styled pictures. Moreover, ultralow differences in local optical density can be revealed in high-intensity, multicolor contrast. There is no contradiction between morphology and art. Quite the contrary, it is said that art, or beauty, is in the eye of the beholder.

Histological Pop Art was also published for the annual session of the Working Group on Dermatological Histology in Saarbruecken, for the German Pathology Days in Berlin, for “Art in the Cafeteria” at the University Hospital of the Saarland, and in several German and international scientific journals.¹⁻⁴

2. MATERIALS AND METHODS

For histopathological examination and fixation of the specimen, the fresh tissue was immediately inserted into 4% formalin, which penetrates into the tissue at the rate of about 1 mm per hour. Thus, the time necessary for fixation is determined by the specimen’s thickness. Only well-fixed sections ensure high quality of preparation and hence

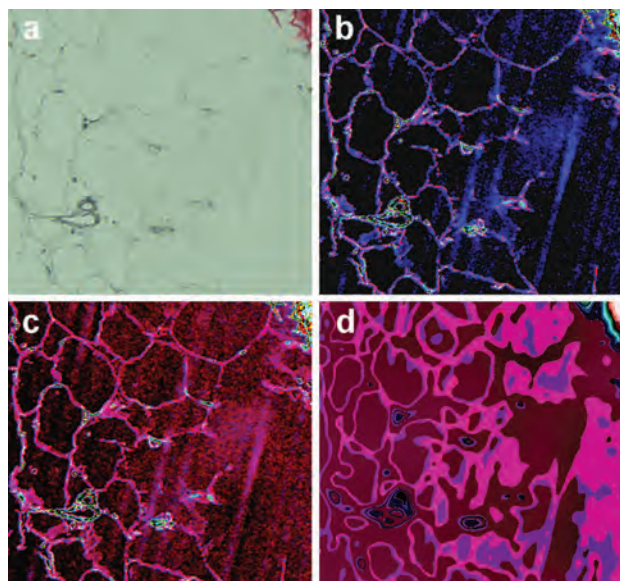


Fig. 2. Section of fat tissue, appearing nearly colorless, bright field (a), digital contrast amplification of the cell contours in blue and red (b, c), advanced abstracting alienation to Pop Art–like colored linear and two-dimensional patterns (d). Preparation and photomicrograph: Anne Kerber, post processing: Jörg Piper (b, c), Anne Kerber (d).

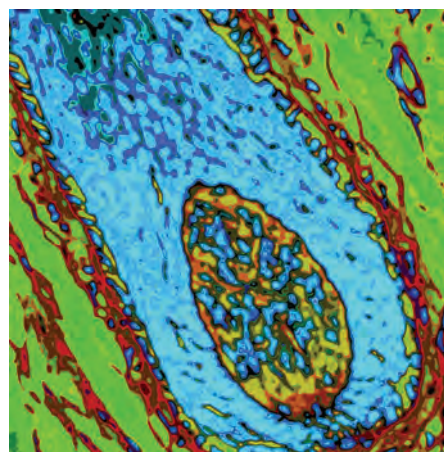


Fig. 4. Hair follicle: longitudinal section, close-up from Figure 3.

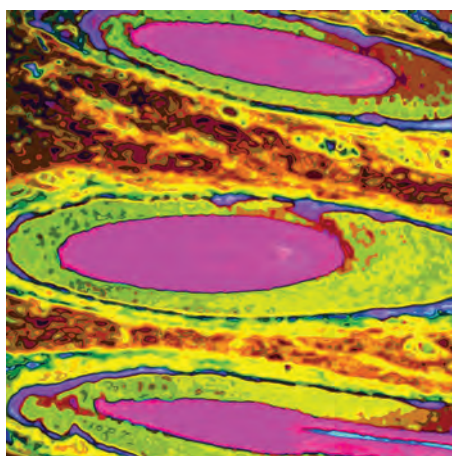


Fig. 5. Several hairs: longitudinal section.

an exact diagnosis. After the tissue was fixed, the sample was automatically embedded using an automated embedding device (Tissue Tek VIP 6, Sakura Finetek, Torrance, CA, USA). This dehydrated the tissue via increasing addition of alcohol in tiny steps; the alcohol was finally replaced by paraffin. During the external embedding, the tissue samples were placed into moulds along with liquid paraffin wax. The small paraffin blocks containing the respective tissue samples were then divided into 3–5- μm sections from the paraffin blocks with a Leica RM2235 rotary microtome (Leica Microsystems, Wetzlar, Germany) and mounted on coated slides. After drying, the paraffin was removed by xylene followed by a descending alcohol series, so that, at the end of the process, the sections were fixed on a glass slide in an aqueous medium. Then, various histological staining was carried out to create a well-contrasted overview of the whole section or highlight particular features of interest. For her “Histological Pop Art” the author used such common staining methods as hematoxylin-eosin, Mallory’s trichrome, Masson-Goldner trichrome, Azan staining by Specht, and various staining

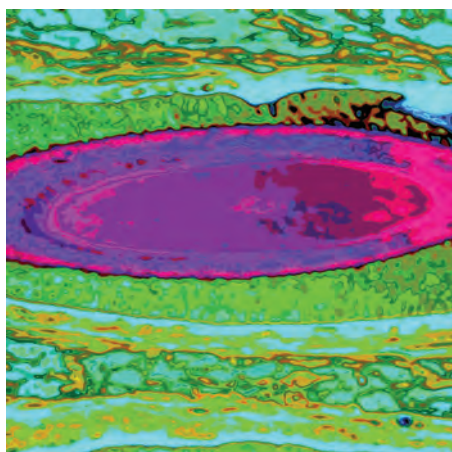


Fig. 6. Hair fiber: cross section, close-up with surrounding root sheets.




Fig. 7. Hair fiber: cross section with medulla, cortex, and cuticle, more detailed.

methods to highlight the elastic fibers and muscles. For observation and photomicrography, an Olympus BX 50 microscope, fitted with 2-, 10-, 20- and 40-fold magnifying lenses and an integrated system camera (U-MDOB), were available. The camera was connected to a computer with the Analysis program of Olympus. Areas or details of interest and artistic value were selected in low magnification and then photographed in their appropriate magnification. Images taken in bright-field illumination were converted to multicolor artwork by special procedures of computer-based post processing. For this purpose, the author used all the tools of modern software for digital image rendering implemented, for example, in Adobe Photoshop (Adobe Systems, San Jose, CA, USA).

3. RESULTS AND DISCUSSION

The main structures of the tissue are still clearly visible after Pop Art processing, but they are accentuated by extraordinary color contrast and exceptional clarity of

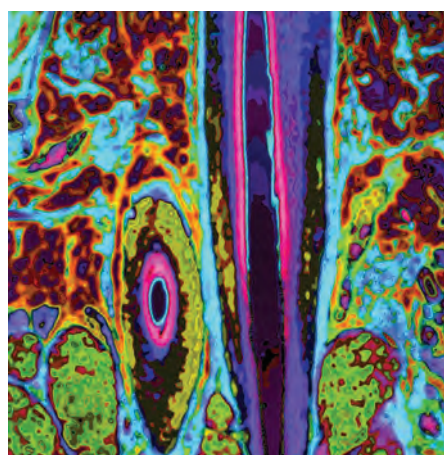


Fig. 8. Hair follicle: one longitudinal and one cross-section together with sebaceous glands.

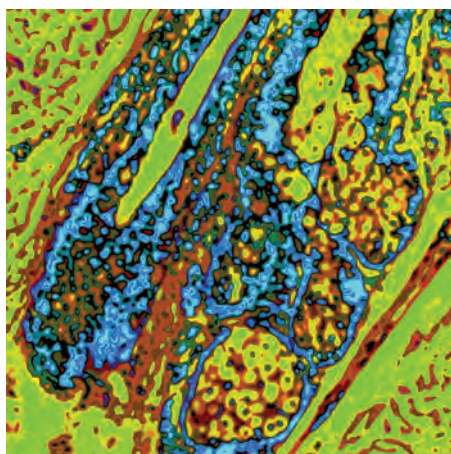


Fig. 9. Hair shaft with sebaceous glands.

textures. Thus, histological sections showing “simply hair” can be converted into impressive artwork characterized by a high grade of aesthetic appeal that delights not only histopathologists but also viewers without a medical education. At first glance, they are usually fascinated with the high variability and intensity of colors. On closer inspection, however, they become interested in the individual structures and finally, when the specimens are explained, the histological microcosm opens up to them as a very special experience (Figs. 3–12).

Through a variety of experiments it was shown that, despite the far-reaching possibilities of digital alienation, the character of final images is influenced by the initial colorization or staining of the specimen. Consequently, histological staining must be included in the planning process of artistic creation. Since thin sections in the range of 3–5 μm on pre-coated slides were applied in exact planarity and photographed with plane objectives, all images were free from relevant indistinctness up to about 400-fold magnification. These qualitative properties of preparation and their output images guaranteed even Pop Art alienation, which is characterized by maximum sharpness.

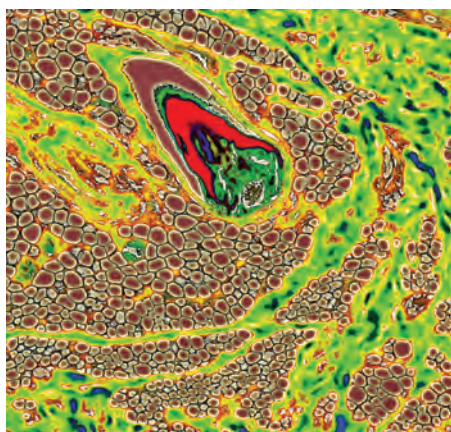


Fig. 10. Small hair: longitudinal section, with enclosed fat and connective tissue.

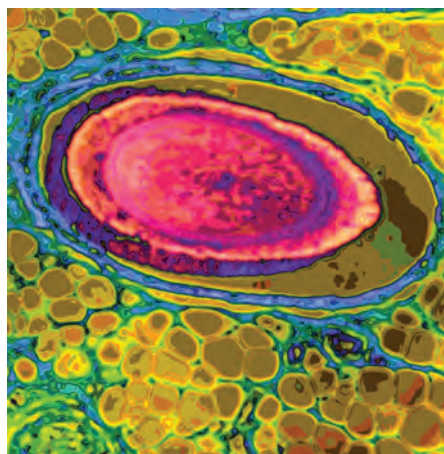


Fig. 11. Hair: cross-section with surrounding fat and connective tissue.

Figures 1(a and b) give an impressive example of histological Pop Art compared with a conventional bright-field image of the same insights. By converting the bright-field image into a Pop Art–styled image, not only are the colors and structures of hair intensified in an incredible way, but the surrounding fat cells, for example, that are nearly emptied by the embedding process (much of the fat is dissolved from the tissue by the alcohols and xylenes), appear filled with nuanced colors after Pop Art transformation. Also, the smallest differences in the density of substances such as are found, for example, in the gap around hair, and even voids are visible as if by magic because even very low differences in regional density are transformed in intensive multicolor contrast.

Beyond artistic tasks and aesthetical appeal, digital colorization and alienation is a sufficient tool for contrast enhancement, especially in very low density specimens. Figure 2 shows a nearly colorless histological section of fat tissue taken in bright-field (Fig. 2(a)). The marginal contours of the fat cells are barely visible because of their low contrast. By digital post processing including

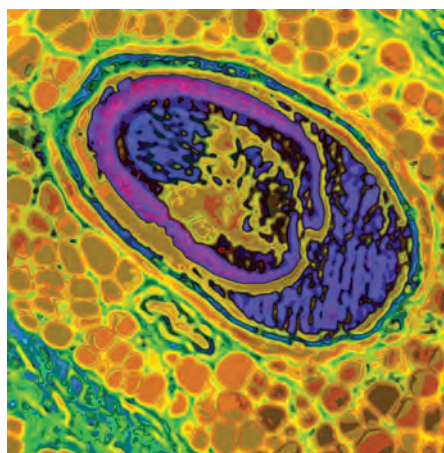


Fig. 12. Hair: a quite diagonal section with surrounding fat and connective tissue.

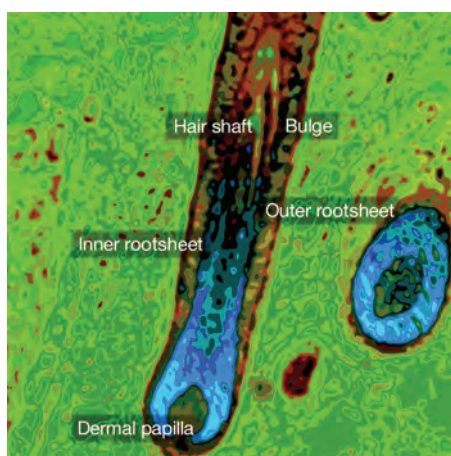


Fig. 13. Hair follicles: longitudinal section with root sheets, hair fiber, and dermal papilla.

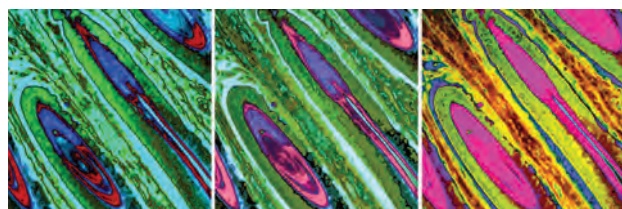


Fig. 14. Triptych of the same structure as in Figure 13 in different colorization.

colorization, these contours can be impressively enhanced and highlighted in red or blue (Figs. 2(b and c)) without compromising the specimen's true fidelity. When compared with optical methods of contrast augmentation, digital amplification of contrast as shown in Figures 2(b and c) is free from haloing, blooming, scattering, or pseudo relief effects—artifacts generally seen in phase contrast, dark-field, or interference contrast images. Thus, digital modulation of contrast can be regarded as a complementary technique leading to a special quality of contrast effects. For artistic purposes, however, the genuine structures of the specimen can be alienated further so that more abstract linear and two-dimensional patterns arise (Fig. 2(d)). In this image, the true fidelity of the specimen might be reduced, but the aesthetic appeal is significantly enhanced.

4. CONCLUSIONS

Digital photography and computer-based post processing enable us to explore new, creative ways and dimensions in aesthetic imaging. Thus, biological objects, especially histological sections, can be converted to artwork characterized by a particular aesthetic appeal. Such artwork can also be used for design in various functional spaces. Beyond

its creative aspects, histological Pop Art can also be useful for didactic purposes (Fig. 13). For instance, a “journey through the human skin” can be realized, leading to all structures of this large organ. Specimens can be presented with extraordinary splendor and clarity. Histological Pop Art images can act as eye-catchers, making visual events much more impressive than classical photomicrographs based on usual bright-field illumination. By digital processing, histological pictures give completely new insights into tissue structures, which evoke associations with several objects or living creatures. Thus, the viewer's fantasy is stimulated. By these means, photomicrographs of histological sections can be transformed into objects of art. Also, a series of images, for example a triptych of different structures in the same color scheme or the same structure in a different colorization may be a decorative way to present histological slides (Fig. 14). Such images can also be used to decorate private living rooms or rooms and buildings outside the personal sphere of life, such as hotels, offices, reception and conference rooms, schools, social institutions, hospitals, and therapy areas. When histological Pop Art is used for creative interior decoration, colorization and atmosphere of images might be adapted to the atmosphere and functionality of the respective areas, so that even their color-psychological aspects would be taken into consideration. The histological Pop Art images shown here have a high degree of vitality induced by their vivid colors and dynamic shapes combined with a typical harmony. In spite of this vitality, the pictures rest in themselves. Their harmonizing effect is supported by the predominantly square shape; any imbalance or “stress” caused by different-sized transverse and longitudinal edges are lifted in a square image. Thus, this art has the potential to elicit positive feelings in the viewer, to enhance mood, and induce revitalizing effects. It may also promote relaxation and induce de-escalation. All in all, histological Pop Art can target designs of functional spaces.

Beyond the artistic aspects discussed above, these techniques of digital post processing could also be used to accentuate fine structures and details characterized by very low regional thickness and optical density. In this respect, such post processing could also lead to further developments in microscopic imaging and documentation.

References and Notes

1. A. U. Kerber, T. Vogt, and C. S. L. Müller, *Aktuelle Dermatologie* 41, 255 (2015).
2. A. U. Kerber, T. Vogt, and C. S. L. Müller, *American Journal of Dermatopathology* (2015), In press.
3. A. U. Kerber, *PSO Magazin* 4, 16 (2015).
4. A. U. Kerber, *Dermato Endocrinology* 3, Cover (2013).

Received: 17 August 2015. Accepted: 10 September 2015.